



PANCREATIC MORPHOLOGY IN HYPOTHYROIDISM

Niyozov Norbek Qurbonovich

Tashkent State Medical University, Tashkent, Uzbekistan

Otabekova Kholida Otabekovna

*Tashkent State Medical University, Tashkent,
Uzbekistan*

Abstract. *For the study, we used the offspring of rats born from control and experimental white laboratory rats - mothers under conditions of hypothyroidism. The results of the study showed that the introduction of Mercazolil into the pancreatic lobules of experimental rats led to changes associated with the normalization of the structural organization of the pancreatic cranium, interlobular connective tissue with the formation of fibrous tissue components, as well as the disappearance of choroid edema observed in the interlobular connective tissue.*

Keywords: *mercazolil, pancreas, pancreatic lobes.*

Introduction. One of the diseases of the thyroid gland is hypothyroidism, a decrease in the amount of hormones in the body. Changes caused by hypothyroidism occur in the form of pancreatic dysfunction, exocrine and endocrine deficiency in the pancreas. The changes in the pancreas in hypothyroidism are mainly focused on the clinical course, but given the lack of information on the morphological changes in the pancreas, it is of particular importance in evaluating the dynamics of the changes in the pancreas.

Relevance of the work. Among endocrine diseases, thyroid diseases occupy a high place in terms of incidence. The incidence of manifest hypothyroidism is 0.2-1%, and latent primary hypothyroidism is 7-10%. Metabolic changes observed as a result of a deficiency or excess of thyroid hormones in the body also lead to morphological and functional changes in the gastrointestinal tract. Gastrointestinal diseases are among the most common diseases in different regions of the world. In order to prevent this from negatively affecting people's lives, it is necessary to expand



modern diagnostic capabilities in detecting the disease, and the emergence of various conditions that lead to an increase in the incidence of the disease.

According to the World Health Organization (WHO), studies conducted in Australia, Europe, Central Asia, the Middle East, and North America show a prevalence of gastrointestinal diseases in the population of 7-41%, with an average of 25%. According to 2016 data, 50-80% of the adult population in most countries suffers from pancreatic diseases.

According to statistics, 5-10% of the population of different countries suffers from pancreatic disease alone. It has been found that pancreatic disease is more common in men than in women. 32% of patients under the supervision of the dispensary have diseases of the digestive system. This disease in many cases causes significant financial losses to the patient and the state budget due to the temporary loss of working capacity for a long time, the high cost of treatment and rehabilitation processes. According to the State Statistics Committee, 59.3% of deaths recorded in January-June 2020 were due to diseases of the circulatory system, 9.5% to tumors, and 4.9% to diseases of the digestive system. As of January 1, 2022, it was revealed what diseases the population mainly suffers from in Uzbekistan. Diseases of the digestive system are in second place among the population after diseases of the respiratory system.

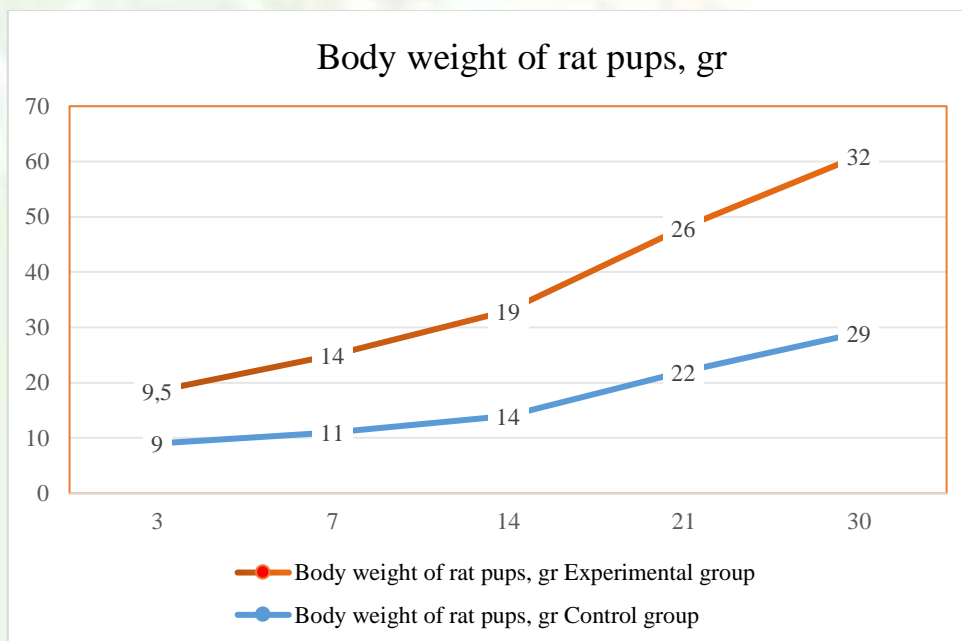
Purpose: To determine the nature of morphological and morphometric changes in the pancreas in experimental hypothyroidism.

Materials and methods of research. To achieve the goal of the study, laboratory rats from control and experimental white laboratory rats under conditions of hypothyroidism were used. The first group comprised a control group of healthy rats. Female rats in the control group were given 1.0 ml of distilled water and 1.0 ml of 1% starch suspension every morning to reduce the harmful effects of oral gavage on the rats' stomachs. Group 2 consisted of the experimental group, in this group 20 female white laboratory rats were given Mercazolil at a dose of 0.5 mg per 100 g of body weight for 14 days to induce experimental hypothyroidism. Then the rats were given Mercazolil at a dose of 0.25 mg per 100 g of body weight for 1 month. Female



rats continued to be given Mercazolil at a dose of 0.25 mg per 100 g of body weight during lactation, both after pregnancy and after birth. A subcutaneous catheter was used as a probe.

Results and Discussion. The rat pancreas is located asymmetrically in the abdominal cavity and occupies the subgastric area. With an increase in body weight, the absolute weight of the pancreas increases significantly. The highest rate of rat weight gain occurs on the 14th day (50%). From the age of newborn to 21 days, the weight of the rat increases 3 times, and the weight of the pancreas - 1.7 times. In newborn rats, the weight of the pancreas is 1.75% of the body weight. With increasing age, the relative weight of the pancreas relative to body weight decreases and on the 21st day of postnatal ontogenesis is 1.1% (Fig. 1).



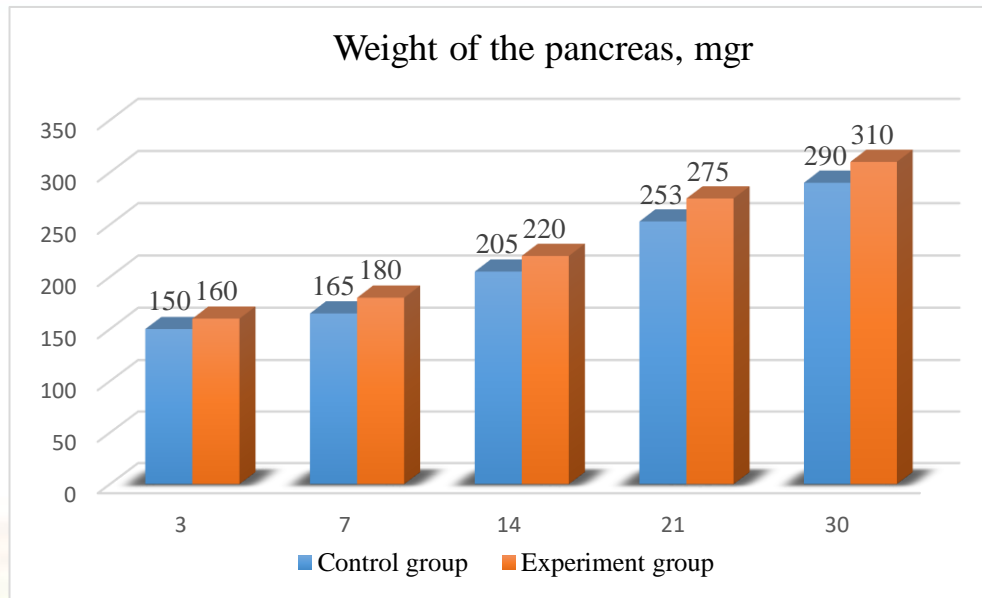


Figure 1. Body and pancreas weights of rat pups.

The shape and size of the pancreas continuously change at different ages during postnatal ontogenesis. Since all anatomical parameters in newborn rats are almost the same, in most cases their pancreas has an isosceles shape. During the early postnatal ontogenesis, the growth of the length, width and thickness of the pancreas does not occur uniformly. Starting from the 7th day, the length of the pancreas grows faster than its width and thickness, as a result, the shape of the pancreas is elongated. The highest growth rate of anatomical parameters was observed in 7-day-old rats, and in 21-day-old rats, an increase in the width of the pancreas ensured its prismatic triangular shape. It was found that all dimensions of the pancreas of the rats in the experimental group were larger than those of the control group. (Fig. 2).

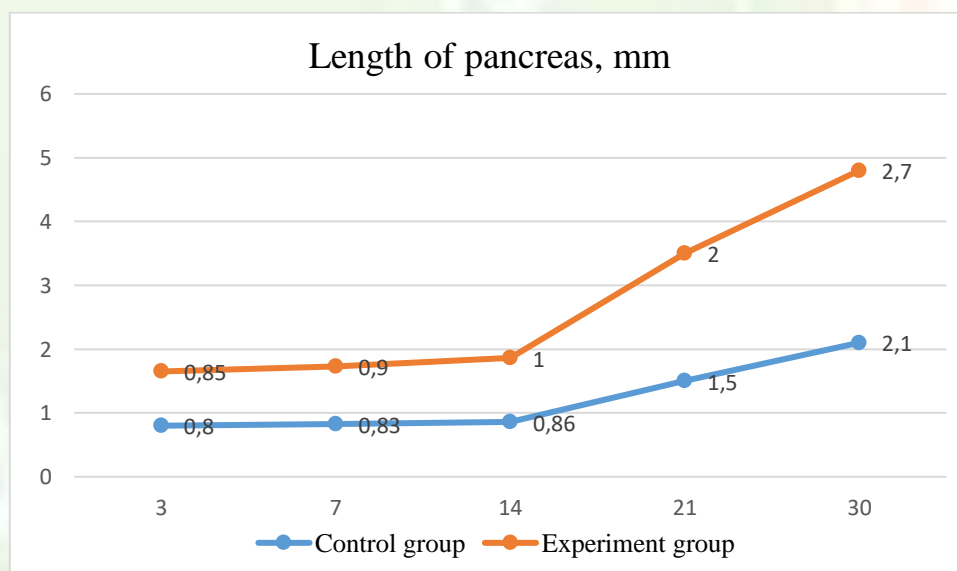


Figure 1. Length dimensions of rat pup pancreas

Thus, it was found that the body weight and the weight of the pancreas of the experimental group of rats were greater than those in the control group. The results of our studies showed that a significant increase in body weight and the weight of the pancreas was detected at 14 days. Compared with the control group, the body weight was 35% greater, and the weight of the pancreas was 19%. When comparing the length, width and thickness of the pancreas, an increase in the dimensions of 2% to 9% was observed in the experimental group compared to the control group.

The pancreas is the most important organ of the digestive system, structurally it consists of two parts, and morphofunctionally - exocrine and endocrine parts (Fig. 3). The pancreas of rats in the control group is covered with connective tissue from the outside, and this capsule forms thin layers and penetrates deep into the gland. Trabeculae divide the gland into separate lobes, the dynamics of which in the thickness of the trabeculae changes from 3 days to 30 days is shown in the diagram. Numerous terminal compartments (acini) are visible inside the lobe and are separated from each other by a thin, sparse connective tissue membrane. The acini are pyramidal or oval in shape, with a wide base resting on the basement membrane.

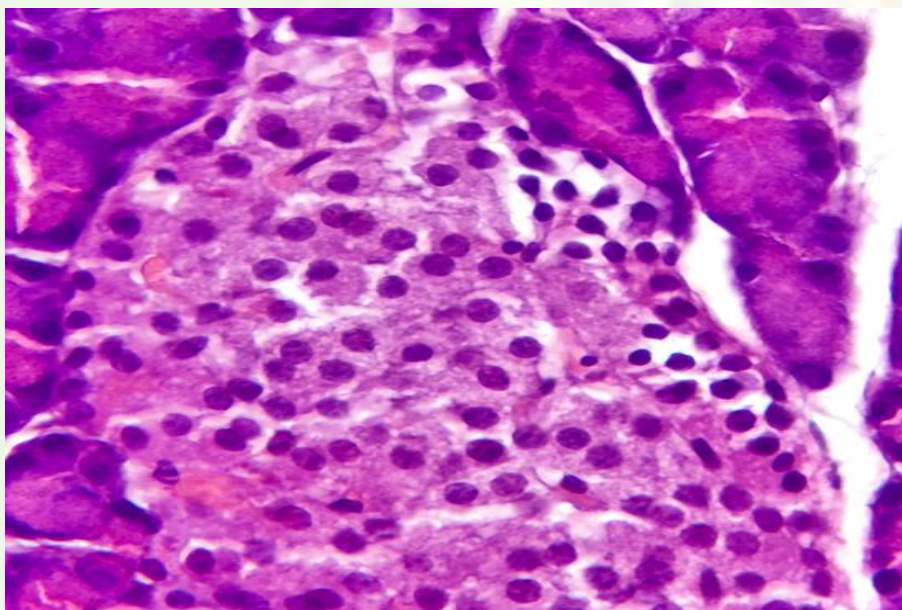


Figure 3. Appearance of the endocrine and exocrine parts of the pancreas of baby rats in the 14-day experimental group. Hematoxylin-eosin staining.

The acinus is lined with a single-layered cuboidal epithelium. In mature acini, zymogenic (zymogenic granules) and homogeneous (rough endoplasmic reticulum and ribosomes) zones can be seen. Numerous terminal compartments (acini) are visible inside the lobe and are separated from each other by a thin, sparse connective tissue membrane. The acini are pyramidal or oval in shape, with a wide base resting on a basement membrane. The acinus is lined with a single-layered cuboidal epithelium. In mature acini, zymogenic (zymogenic granules) and homogeneous (rough endoplasmic reticulum and ribosomes) zones can be seen. In the early stages of the experiment, the segmental structure of the organ is preserved, and scattered interstitial edema is visible. Changes in blood vessels were observed from the 1st day onwards. Increased permeability of microvessels and venous vessels, manifested by dilation of visible vessels, led to the leakage of the liquid part of the blood through the vessel wall into the surrounding connective tissue. At 7 days of postnatal ontogenesis, the growth rate of the diameter of the acinar cell in the experimental group decreased by 2.5%, and the height by 8% compared to the control group. By the 14th day of the experiment, morphological examination of the pancreas showed an even greater development of changes in the vessels. An increase in edema was noted in the stroma, mainly in the perivenular and pericapillary spaces (Fig. 4).

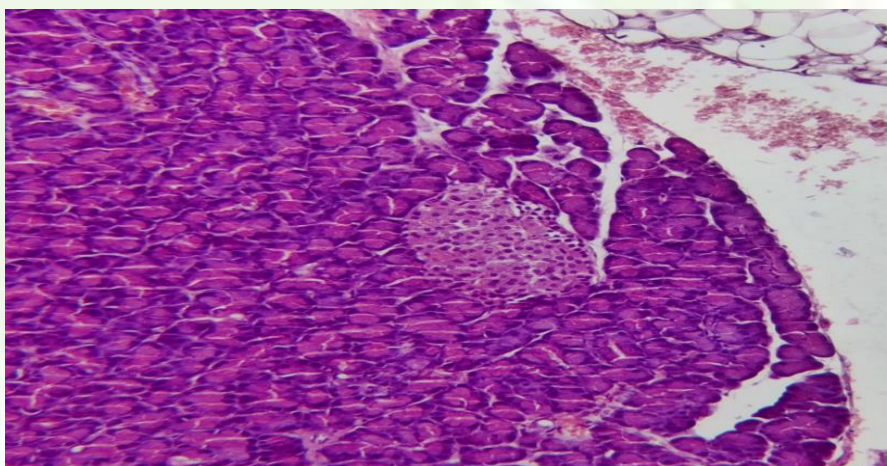




Figure 4. Pancreas of baby rats in the 14-day experimental group an increase in edema was noted in the stroma, mainly in the perivenular and pericapillary spaces. Hematoxylin-eosin staining.

During this period of the experiment, collagen fibers were swollen, loosened, the capsule was unevenly located, edema of connective tissue was observed, and the diameter of the capillary blood vessels increased by 1.2 times compared to the previous group. When comparing acinus cell diameter and height compared to the control group, acinus diameter was delayed by up to 3% and height by up to 12% in the experimental group. These changes were evident at 14 days.

Conclusion. The results of the study showed that the introduction of Mercazolil into the pancreatic lobules of experimental rats led to changes associated with the normalization of the structural organization of the pancreatic cranium, interlobular connective tissue with the formation of fibrous tissue components, as well as the disappearance of choroidal edema observed in the interlobular connective tissue. In addition, the intensity of the symptoms of destruction of the terminal secretory section of the lobules decreased and at the same time the number and height of the pancreas in the lobules increased. This may be due to the intensification of the process of division of the pancreas and the activation of the secretory process. In the endocrine part of the gland lobules, a thickening of the arrangement of insulinocytes in the islets and a decrease in areas filled with a loose connective tissue layer were observed; in addition, the size of the islets increased and became larger than in control animals. This may indicate a general increase in the number of endocrine cells in the gland, and therefore an increase in hormone production.

REFERENCES

1. Akhmedova S. M. et al. Pancreatic morphology in hypothyroidism // International journal of artificial intelligence. – 2024. – T. 4. – №. 09. – S. 475-479.
2. Akhmedova S. M., Niyozov N. K., Nisanbaeva A. U. Structural changes in pancreatic disease in hypothyroidism // Modern scientific research: current issues, achievements and innovations. – 2023. – S. 156-158.



3. Kurbanovich N. N., Abdurasulovich G. D. Features of morphological changes in the pancreas // Texas Journal of Medical Science. – 2023. – T. 16. – S. 79-83.
4. Kurbanovich N. N. et al. Reactive changes in the pancreas in hypothyroidism // American Journal of Interdisciplinary Research and Development. – 2024. – T. 25. – S. 343-347.
5. Mukhamadovna A. S. et al. Indicators of Fetometry of the Fetus in Pregnant Women in a State of Hypothyroidism // Texas Journal of Medical Science. – 2023. – T. 16. – S. 75-78.
6. Mukhamadovna A. S. et al. Morphological Characteristics of Myocardial Changes When Exposed to Pesticides // Onomazein. – 2023. – №. 62. – S. 1226-1237.
7. Matkarimov O., Axmedova S., Niyozov N. Criteria for assessing structural changes in the myocardium in experimental hypodynamic and diabetes // Central Asian Journal of Medicine. – 2025. – №. 3. – S. 273-283.
8. Muminov O. B., Niyozov N. K., Nisanbaeva A. U. Scientific Medical Bulletin of Yugra // Scientific Medical Bulletin of Yugra Founders: Xanthi-Mansiysk State Medical Academy. – 2021. – T. 1. – S. 141-143.
9. Niyozov N. et al. Medical sciences // Art studies. – S. 36.
10. Niyozov N., Ergashev S. Pancreatic morphology in thyroid diseases in white mice // Modern Science and Research. – 2025. – T. 4. – №. 4.
11. Niyozov N. K. et al. Morphological Aspects of Pancreas Changes in Experimental Hypothyroidism // Journal of education and scientific medicine. – 2023. – T. 8. – №. 2. – S. 27-31.
12. Niyozov N. K. et al. Morphology of the Pancreas Against the Background of Hypothyroidism // Journal of education and scientific medicine. – 2024. – T. 18. – №. 5. – S. 47-52.
13. Niyozov N., Kukonboyev M. Pancreas morphology in experimental hypothyroidism // Modern Science and Research. – 2025. – T. 4. – №. 3. – S. 798-806.



14. Niyozov N. K., Kukonboyev M. I. Pancreatic gland morphology in experimental hypothyroidism // Modern Science and Research. – 2025. – Т. 4. – №. 4. – С. 1169-1176.
15. Niyozov N. Characteristics of morphological changes in pancreatic disease in experimental diabetes mellitus // Modern science and research. – 2025. – Т. 4. – №. 3. – С. 1083-1093.
16. Rakhimova M.O. and dr. Fetometric indicators of pregnancy and hypothyroidism // Conference of the Org Committee. – 2021. – С. 143.
17. Sagatov T.A. and dr. Morphological state of the microcirculatory bed and structure of the uterine tissue in chronic intoxication with the pesticide Vigor // Problems of Science. – 2019. – №. 2 (38). – С. 56-60.
18. Sadikova Z.Sh. et al. The state of female genital organs during postnatal development of offspring under conditions of intrauterine exposure to pesticides // Morphology. – 2020. – Т. 157. – №. 2-3. – С. 183-183.
19. Umerov A. A., Niyozov N. Q. Pancreatic pathologies: understanding the interplay between chronic diseases and metabolic dysfunction // Conference on the role and importance of science in the modern world. – 2025. – Т. 2. – №. 1. – С. 104-107.
20. Umerov A. A., Niyozov N. Q. Pancreatic morphology in experimental stress // Multidisciplinary Journal of Science and Technology. – 2025. – Т. 5. – №. 1. – С. 223-227.
21. Umerov A., Niyozov N. Pancreatic morphometry under stress // International journal of medical sciences. – 2025. – Т. 1. – №. 1. – С. 362-368.